

EXTREME CLASS IV COMPOSITES: THE NEXT BEST THING TO CLONING



by Michael J. Morgan, DDS
Hinsdale, IL
www.smilesbymorgan.com

ABSTRACT

The restoration of a large Class IV fracture or the replacement of defective composites in the anterior dentition can be extremely challenging. Direct resin restorations are often the treatment of choice for patients who are more conscious of the conservation of tooth structure and are seeking alternatives to porcelain veneers and full-coverage crowns. Single-shade restorations will not adequately match the natural tooth structure and adjacent dentition and, therefore, will not satisfy most patient expectations. The replication of natural polychromicity is the key to restoring natural esthetics and harmony. It is the clinician's responsibility to become familiar with and skilled in the use of multilayered and multi-chromatic resin restorations. An array of resin systems exists today that enable the clinician to achieve long-term, natural-looking esthetic results while maintaining the natural tooth structure.

It is the clinician's responsibility to become familiar with and skilled in the use of multilayered and multi-chromatic resin restorations.

INTRODUCTION

CLINICAL ADVANTAGES

Patient demand for improved esthetics, coupled with the desire for conservative treatment, has driven clinicians to improve their skills with direct resin. Over-preparation of anterior teeth and overuse of indirect restorations, particularly in the anterior dentition, has come under question by a segment of our profession. Conservation of tooth structure is one of the most important clinical advantages that direct resin restorations have over indirect composite or porcelain restorations.¹ Direct resin restorations are inherently

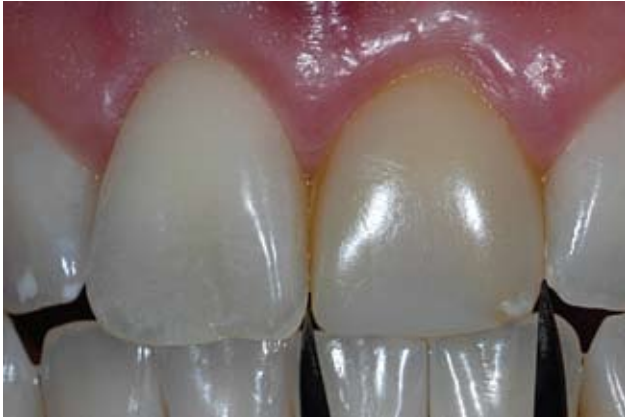

Figure 1: The patient desired improved esthetics of his upper left central incisor. Note that the width of the centrals was measured for symmetry.

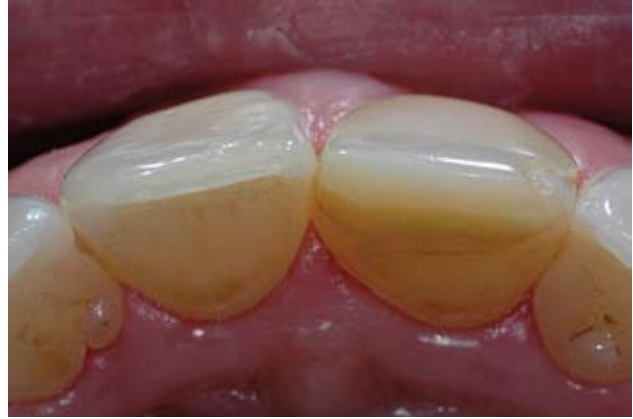

Figure 2: Contours viewed from the incisal aspect reveal that the existing restoration had asymmetrical contours on the buccal and lingual that contributed to deficient esthetics.

conservative in nature and do not follow the historic GV Black preparation designs.

Direct resin restorations require the removal of only the current restoration and any carious tissue, and the placement of an appropriate bevel or finish line. Less invasive than indirect alternatives, direct resin treatment requires limited to no reduction of healthy tooth structure. "Direct resin restorations are made to fit the requirements of the tooth, instead of the tooth made to fit the requirements of the restoration."²

Renewability is a unique advantage of direct resin restorations compared to indirect alternatives.³ Porcelain materials are difficult to repair predictably unless the entire restoration is removed. Small resin fractures or incipient lesions can be repaired or restored conservatively and predictably. Should a tooth require endodontic treatment after placement of a resin restoration, the access opening and core buildup can be completed with resin, also.

The high-gloss finish that may be lost over time from resins, particularly hybrids, can be readily polished and resealed when necessary. Of all the materials available today

for the restoration of the anterior dentition, resin exhibits wear rates closest to those of enamel⁴ and results in minimal abrasion of opposing dentition, particularly when compared with the abrasion caused by feldspathic porcelain.

From a clinician's standpoint, another benefit of direct resin restorations is the artistic satisfaction derived from the recreation of natural beauty. The successful combination of restorative and artistic skills results in a restoration that is highly esthetic and functionally sound. Unlike laboratory-fabricated restorations, the final outcome of direct composite restorations is entirely controlled by the clinician, who may choose from a palette of resin colors. Drawing on personal experience and technique, the skills of the individual clinician are revealed in the ultimate artistic expression in dentistry. Fortunately, a variety of excellent direct resin systems is available to enable dentists to predictably create simple and complex multi-chromatic restorations while maintaining current natural tooth structure. Manufacturers have developed new generations of products that can mimic the diverse anatomical, opti-

cal, and polychromatic properties of the natural dentition.⁵ The physical properties of direct resin materials also have been enhanced to increase strength, durability, and long-term function.

MATERIALS

Among the direct resin materials available to enable clinicians to achieve predictable and esthetic results are Aelite Esthetic Composite (Bisco; Schaumburg, IL); Filtek Supreme Plus (3M ESPE; St. Paul, MN); Esthet•X (Dentsply Caulk; Milford, DE); Four Seasons (Ivoclar Vivadent; Amherst, NY); and Gradia Direct (GC America; Alsip, IL). These products can be used for anterior and posterior restorations and demonstrate various enhancements in handling characteristics, shade matching, optical properties, polishability, and overall esthetics, according to the respective manufacturer's data.

This article details the clinical restoration of a fractured maxillary central incisor using a combination of esthetic restorative systems. In addition, two complex Class IV restorative cases are briefly reviewed.

CASE 1

A 32-year-old male presented with a discolored maxillary left central incisor that he desired to have esthetically enhanced. The patient had had the same restoration replaced multiple times previously (Fig 1). Complete and thorough clinical, radiographic, and photographic examinations were performed.

The patient's age, the amount of tooth structure missing, the adjacent dentition, the polychromicity of the area to be restored, and the intricate facial anatomy were all factors considered during treatment planning. Digital photographs in color and black-and-white were reviewed with the patient. After discussing all treatment alternatives, a direct resin restoration was chosen to rejuvenate the maxillary central incisor.⁶ The patient was informed that there would be a reevaluation two weeks after the tooth was restored, at which time any discrepancies in color or anatomy could be adjusted and corrected.

OCCUSAL AND GINGIVAL CONTOURS

The patient presented with a Class I occlusion, with no overjet or overbite in the area of teeth #9, #23, and #24. In order to provide improved occlusion and proper tooth length, teeth #23 and #24 were orthodontically moved lingually. A lower Hawley retainer was fabricated and adjusted over a three-month period to move the mandibular teeth into the proper position.

The gingival architecture of tooth #8 was not symmetrical to that of tooth #9. Root angulation asymmetry and thinner gingival tissue caused the margin to migrate slightly apically on tooth #8 compared to tooth #9. A diode laser was used to recontour the gingival tissue of tooth #9

to bring it into harmony with tooth #8 prior to the operative appointment. The patient was given written and oral postoperative instructions for the care of the recontoured site. Over the subsequent four weeks, the gingival health was not maintained around the site, and the tissue migrated incisally.

Of all the materials available today for the restoration of the anterior dentition, resin exhibits wear rates closest to those of enamel.

DEVELOPMENT OF ESTHETICS

There are three methods for restoring the lingual contours, incisal edge position, and occlusion of a fractured central incisor.⁷ The clinician can visually estimate the correct contours and thickness of the resin layers, and a gloved finger can be employed as a lingual stop for the first increment of composite. This method is initially the fastest and easiest for clinicians who are uncomfortable using diagnostic wax-ups. However, it is difficult to correctly estimate the proper contours, which affect not only occlusion but also esthetics.

The second method is to create a diagnostic wax-up on mounted models from the alginate taken at the initial appointment. This provides the clinician with additional time to carefully examine the case and design the exact contours and incisal edge position using a putty stent that is fabricated from the wax-up.

The third method is to fabricate a composite mock-up directly in the mouth. A putty matrix or quick-set polyvinyl siloxane impression can be fabricated from the mock-up to

create a stent for restorative guidance. This method was chosen for this case.

Using this intraoral mock-up method, the occlusion can be adjusted, and the basic shade and contour determined. When viewed from the lingual, it was apparent that the contours of the previous composite restoration were over-contoured on the lingual and under-contoured on the buccal aspects (Fig 2). An egg-shaped carbide polishing bur was used to reduce the excess resin on the lingual of tooth #9. Flowable composite was added to the incisal edges and the facial to create the correct length and contour (Fig 3). Medium finishing discs (Soft-Lex, 3M ESPE) were used to shape the facial and interproximal embrasures. A putty matrix was fabricated intraorally from the mock-up to facilitate and guide the completion of the final restoration.

ESTHETIC ASSESSMENT

The foundation for the replication of natural esthetics is accurate color mapping of the existing dentition. This provides a road map and guidance for the accurate restoration of harmonious form. While the teeth were wet, the value, hue, chroma, opalescence, translucency, incisal halo, and maverick colors were noted and mapped. A custom shade guide was fabricated with individual shades of different manufacturers' composites and used to select the value first. Hue, chroma, and other characteristics were subsequently chosen and noted. The teeth were then dried, and the intricate facial anatomy examined and noted. Digital photographs of the wet and dry stages were taken and placed on a large monitor as reference points during composite placement.

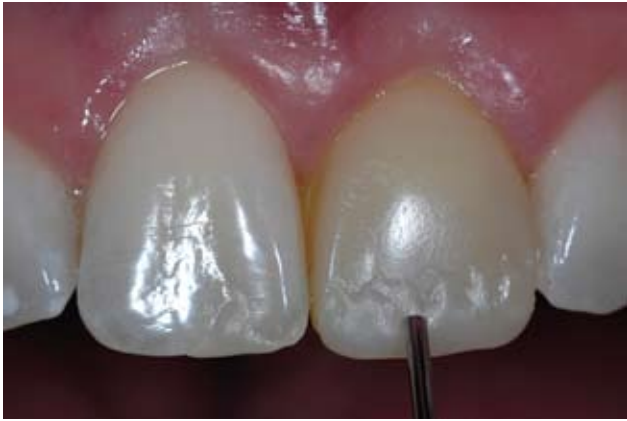

Figure 3: A mock-up was completed using flowable composite to establish the incisal length and contours prior to fabrication of the putty matrix.

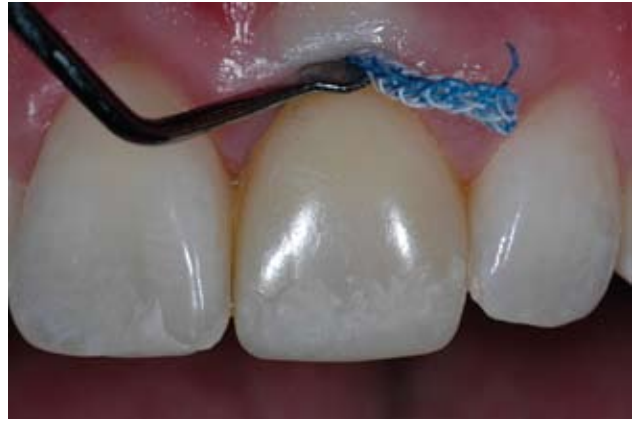

Figure 4: Retraction cord was placed to retract the gingival tissue and prevent infiltration of the adhesive subgingivally and onto the root surface.

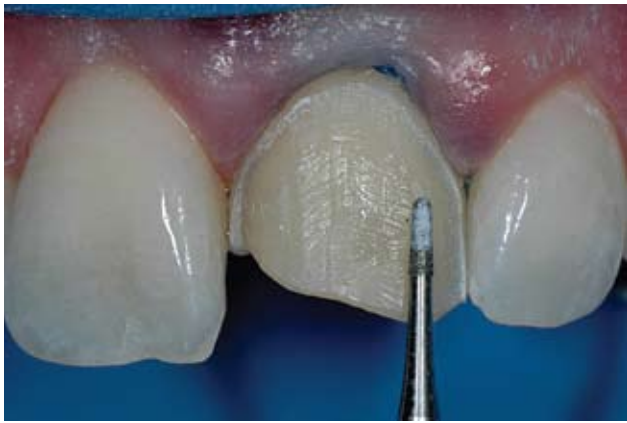

Figure 5: The existing restoration was removed and the preparation smoothed with a fine diamond. A 45° bevel was placed at the fracture line.

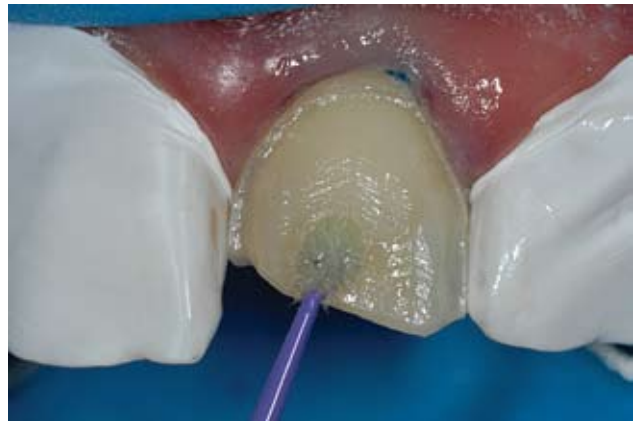

Figure 6: Plumber's tape was used to protect the adjacent enamel. After etching and rinsing, a single component adhesive was placed in two coats.

PREPARATION DESIGN

The patient was anesthetized and a modified rubber dam isolation was established. The teeth were cleaned with pumice and thoroughly rinsed. A single #00 cord (UltraPack Cord, Ultradent Products; South Jordan, UT) was placed subgingivally to retract and protect the gingival margin (Fig 4). Placement of cord prior to adhesive procedures also can prevent the migration of adhesive resin onto the subgingival root surfaces. Light-cured adhesives on the root surfaces can cause subsequent gingival irritation and inflammation.

Proper preparation of this Class IV restoration required removal of the previous large resin restoration. A light and rounded finish line was created using a fine diamond bur (F888-012, Axis Dental; Coppell, TX) to blend the resin restorative margin with the existing tooth structure (Fig 5). The conservative preparation allowed for reflection and deflection of light, which imparted a chameleon effect to the restorative margin.⁸ A 45° bevel was placed along the primary fracture line. This allowed sufficient bulk of resin for strength and as a means to prevent show-through of the fracture line

when the restoration was complete. The lingual area of the fractured tooth was lightly dusted with a fine round diamond bur on high dry to allow for maximum visibility. The lingual enamel margins were then conservatively prepared with the same diamond with water spray.

Plumber's tape was placed on the adjacent teeth to protect the exposed enamel from etchant. The final preparation was etched with 37% phosphoric acid (UltraEtch, Ultradent) for 20 seconds and rinsed thoroughly. Excess water was removed with a high-speed evacuation until the dentin was damp/moist. A single-

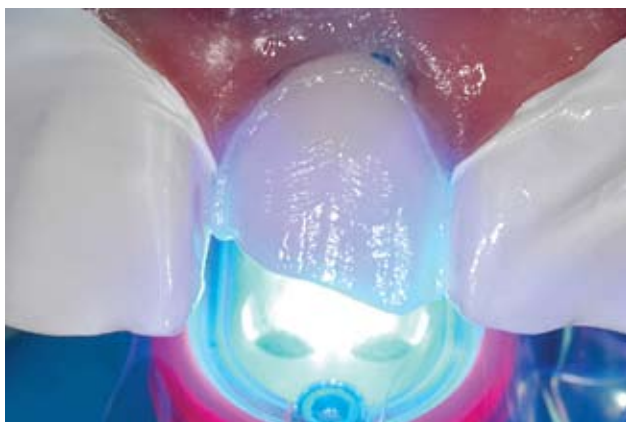


Figure 7: The adhesive was light-cured from the buccal and lingual aspects for 40 seconds each.

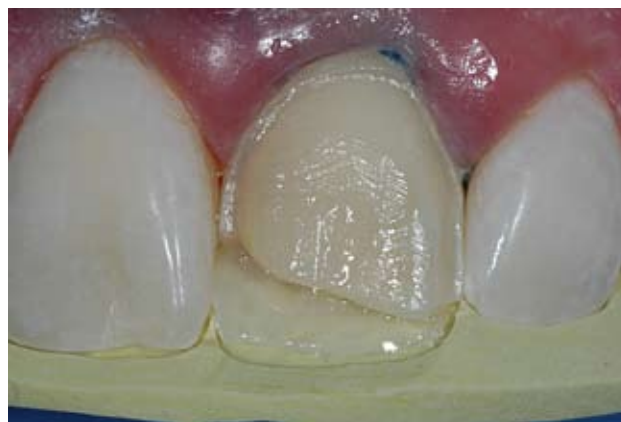

Figure 8: A thin layer of milky white composite was placed in the putty stent to form the lingual enamel shelf and light-cured.

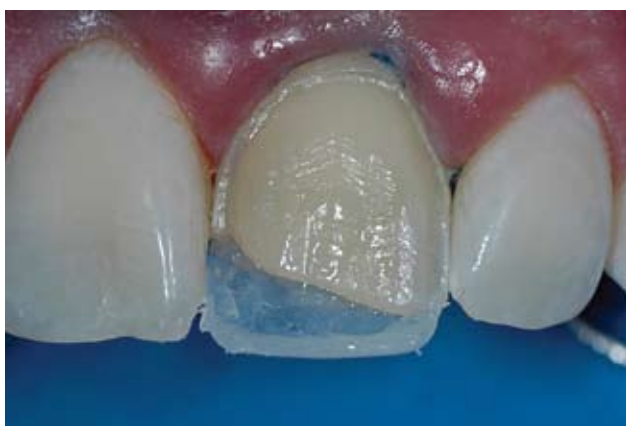

Figure 9: A high-value white composite was added to the incisal edge to create an incisal halo at the predetermined length.

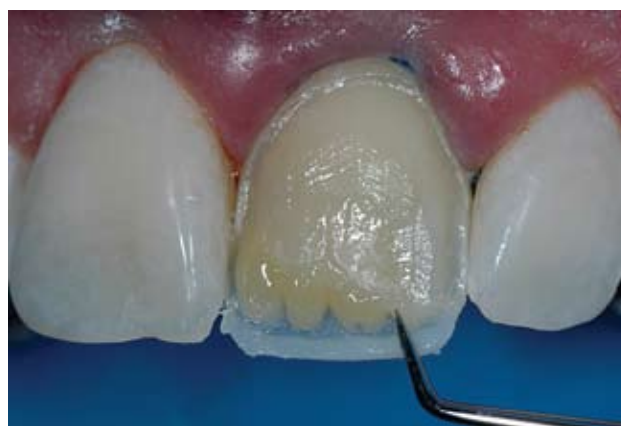

Figure 10: The dentin layers were placed to replicate the lost dentin tooth structure. Mammelons were formed using a sharp instrument.

component bonding agent (One Step, Bisco) was applied with a microbrush (Microbrush; Grafton, WI) in multiple coats using a light scrubbing motion (Fig 6). The area was thoroughly air-dried until all excess adhesive and solvent were removed. The adhesive was light-cured for 40 seconds (Fig 7) with an UltraLum curing light (Ultradent).

POLYCHROMATIC BUILDUP

Anterior direct resin restorations can be fabricated using an anatomical or shaded technique.⁹ The putty matrix was seated over the rubber dam to examine the accuracy

of preparation for the anatomical buildup.¹⁰ A small increment of milky white resin (e.g., Aelite WE enamel; Filtek Supreme Plus white enamel; Esthet•X WE; Gradia Direct WT; Four Seasons enamel bleach light) was placed in the lingual area of the putty matrix approximately 1 mm short of the incisal edge and light-cured for 10 seconds (Fig 8). This layer replicated the fractured and missing lingual enamel.¹¹ The putty stent was removed, since the lingual contour had been established. The incisal halo effect was created with a thin bead of opaque white resin (e.g., Aelite B1 Body;

Filtek Supreme Plus extra white body; Esthet•X W-O; Gradia Direct BW; Four Seasons enamel white effect). A thin blade composite instrument was used to place the effect along the incisal edge and mesial incisal margin (Fig 9). After verifying the incisal edge position with the putty matrix, the increment was light-cured for five seconds. Glass Connector (Micerium; Genoa-Avegno, Italy) was placed over the lingual enamel layer before the placement of the first dentin layer in order to enhance the optical properties. This material mimics the natural protein layer that exists between dentin and

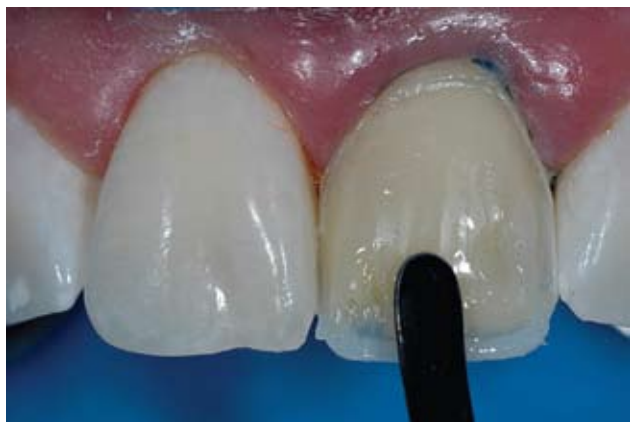

Figure 11: After clear composite was placed in between the mammelons and cured, an enamel layer of high-value composite was placed and slightly under-contoured.

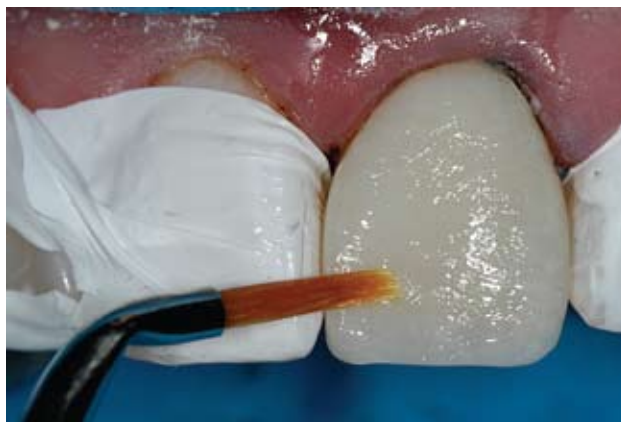

Figure 12: White tint was placed with an artist's brush and then streaked with an endo file to create internal areas of hyper-calcification and characterization.

enamel and is responsible for light scattering in the natural dentition.¹²

The dentin shade noted on the color map (e.g., Aelite A2 enamel; Filtek Supreme Plus A2D; Esthet-X A2; Gradia Direct A2; Four Seasons A2 dentin) was placed over the lingual enameled shell. Irregularities in the dentinal lobes were created and sculpted to create internal dentin mammelons (Fig 10). Care was taken not to over-contour the material in order to provide clearance for the remaining facial layer. The resin was light-cured for five seconds. Clear incisal resin (e.g., Aelite Incisal clear; Filtek Supreme Plus translucent grey; Esthet-X GE; Gradia Direct CT; Four Seasons enamel translucent clear) was placed between the mammelons and the opaque incisal edge to create the illusion of incisal translucency. If necessary, additional translucency can be created in specific areas using the appropriate tints and special effects resins. The translucent resin layer was light-cured for five seconds. Glass Connector (Micrium) was placed over the dentin layers, again before placing of the final enamel layers.

The remaining facial enamel was replicated using a layer of high-value enamel composite (e.g., Aelite WE enamel; Filtek Supreme Plus white body; Esthet-X W; Gradia direct WT; Four Seasons enamel value high). Artists' brushes were used to smooth the facial surfaces to the desired final contours (Fig 11). The resin was feathered out over the scalloped preparation margins and light-cured for 10 seconds. The facial surface was slightly under-contoured using a medium high-speed diamond at medium torque in an electric handpiece.

Replication of the white characterization color that was mapped preoperatively in the adjacent tooth was accomplished with white tint. After etching the composite surface with 37% phosphoric acid and rinsing, a non-hema bonding resin (Porcelain Bonding Resin, Bisco) was applied, air-thinned, and light-cured.

White tint (Creative Color, Kerr; Orange, CA) was added horizontally to the resin surface and streaked with a dry brush tip or endodontic file (Fig 12). Small white clouds or irregularities were created with the brush tip as well. The tint was light-

cured for 10 seconds. A thin layer of clear enamel resin (e.g., Aelite Incisal clear; Filtek Supreme Plus translucent grey; Esthet-X GE; Gradia Direct CT; Four Seasons enamel translucent clear) was placed to cover the tints and create the final facial contours (Fig 13).

FINISHING AND POLISHING

Restorations built to correct anatomical contour require minimal finishing and polishing. Initial finishing was achieved by marking the line angles and facial contours with a red or graphite pencil (Fig 14) and using a medium Sof-Lex disc to blend the composite margins seamlessly with the natural enamel surfaces (Fig 15). Removal of any excess resin from the interproximal areas was achieved using a 12B scalpel and fine diamond finishing strips. Developmental contours and primary facial anatomy were created using a superfine diamond bur (SF859-014, Axis Dental) at the low range of a high-speed electric handpiece. The short light strokes were done initially with water spray and then on high dry for maximum visibility.

Secondary anatomy can be similarly placed using a medium dia-

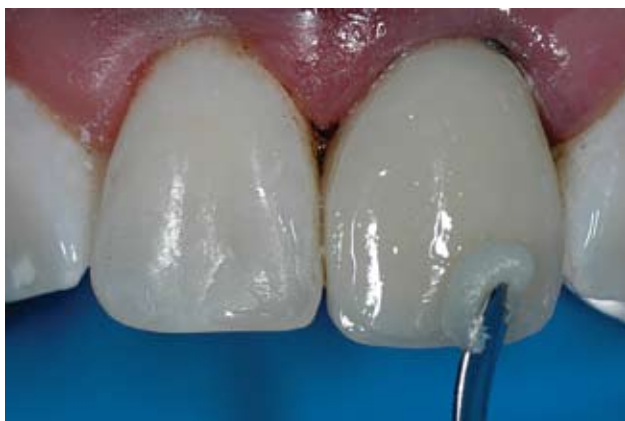

Figure 13: A thin layer of clear enamel composite was placed and slightly over-contoured to allow for finishing.

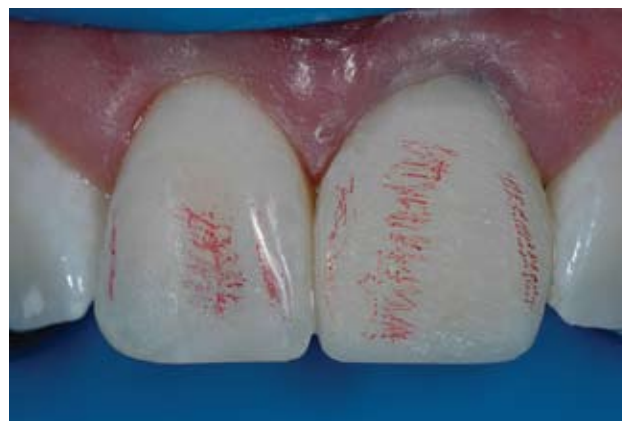

Figure 14: Line angles and contours mimicking the adjacent central incisor were marked with a red pencil.

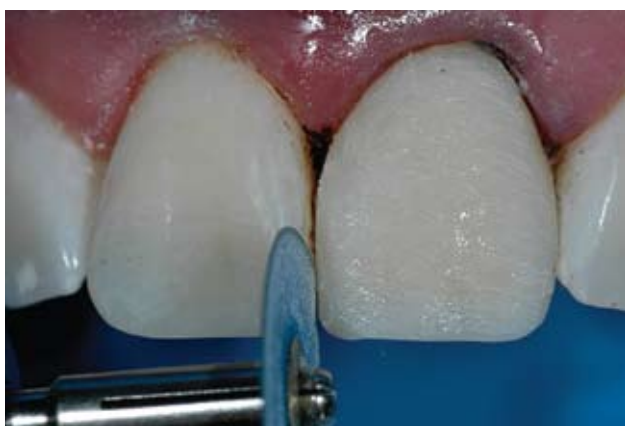

Figure 15: Initial finishing was accomplished using coarse and medium finishing discs to create gross incisal, interproximal, and facial contours.

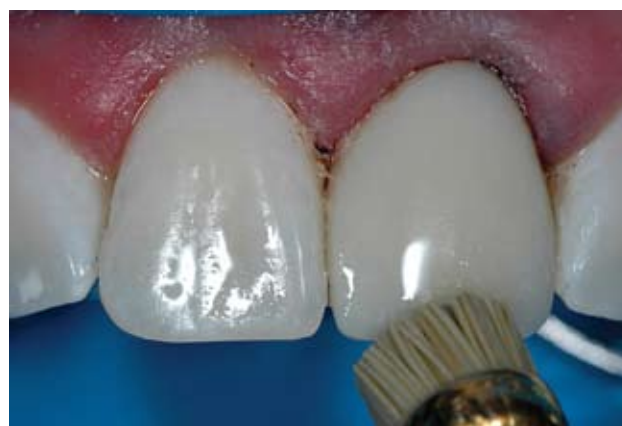

Figure 16: A Jiffy brush with water was used at low speeds to polish the restoration after fine diamonds, rubber cups, and points had been used.

mond to impart horizontal scratches and contours. Care was taken to replicate the facial surface of the adjacent teeth and the original anatomy presented. Optimum visualization of the reflective and deflecting zones ideally can be achieved by placing gray artist's glitter over the facial surfaces. The glitter accentuates the minute changes in light refraction and allows for slight corrections in contour.

The polished facial surface was produced with medium and fine silicone cups and points and a Jiffy brush (Ultradent) on slow speed with

a light intermittent touch (Fig 16). Excessive pressure on the brush can remove facial anatomy and degrade the resin surface by overheating it. The final luster was achieved with a fine diamond polishing paste on a Flexibuff (Cosmedent; Chicago, IL) polishing disc. Excess paste was thoroughly rinsed, and the restoration was examined for overall esthetics.

The rubber dam was removed and the occlusion adjusted. The lingual surface was finished and polished using polishing cups (Enhance, Dentsply Caulk) and a Jiffy brush.

The restoration was then fully light-cured for 40 seconds each from the facial and lingual surfaces.

The patient was re-examined two weeks later to verify functional and esthetic harmony, and any minor occlusal or color adjustments were made at that time. Final digital photographs were taken to verify natural esthetics (Fig 17). One photograph was converted to black and white to verify value. The final restorative results were acceptable esthetically and functionally (Fig 18).

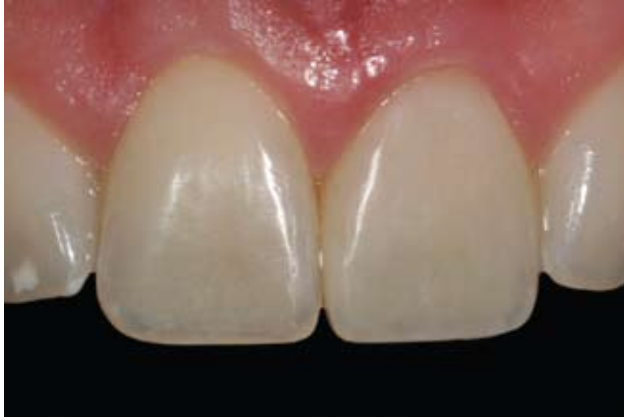

Figure 17: The final restoration demonstrated acceptable esthetics and correct protrusive function with the orthodontically corrected lower incisors.



Figure 18: The patient's final esthetic restoration was in harmony with his natural smile.

CASE 2

A 17-year-old girl fractured her maxillary right and left central incisors during a sporting event. They were originally restored with a single shade of composite, but after less than two years, they had become discolored and rough (Fig 19). The patient's mother was definitively opposed to any type of porcelain restorations, based upon previous family experiences and her knowledge of conservative alternatives. Direct Class IV resin restorations were recommended as the most conservative treatment modality. Removal of the previous restorations revealed a large Class IV fracture and composite veneer on tooth #8 and an incisal fracture on tooth #9 (Fig 20).

The incisal edges of both teeth were highly polychromatic, with white, blue, gray, and amber areas of

translucency and opalescence. The treatment protocol for an indirect wax-up, putty stent, conservative preparation, anatomical buildup, and finishing were followed to restore the incisors to proper form and function (Figs 21 & 22).

CASE 3

An 8-year-old girl presented with a fractured maxillary right central incisor that she had suffered in a bathtub accident at home (Fig 23). Complete and thorough clinical, radiographic, and photographic examinations were performed. The pulp chamber was not directly involved, but a pinkish hue was visible on the lingual aspect of the fractured area. The tooth had no mobility and was not thermally sensitive. The parent was informed that although root canal therapy was not necessary at

this time, it might be required at any time in the future as a result of the trauma to the pulpal tissues. When treatment was complete, the patient would be monitored and reevaluated at three-month intervals for any pulpal changes for the first year.

To prevent bacterial invasion of the pulpal tissues and decrease the opportunity for thermal sensitivity between the examination and operative appointments, a self-etching primer (OptiBond SE, Kerr) was placed according to the manufacturer's specifications and light-cured. Alginate impressions were taken for the fabrication of a diagnostic wax-up and putty stent. At the operative appointment, the tooth was restored using an anatomical build-up technique. The highly characterized areas of white on the facial surface were replicated using two separate

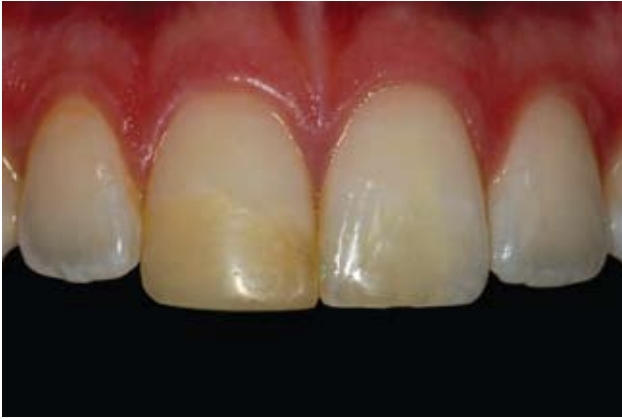

Figure 19: The patient desired improvement of the color and surface roughness of the existing composite resin restorations on her central incisors.

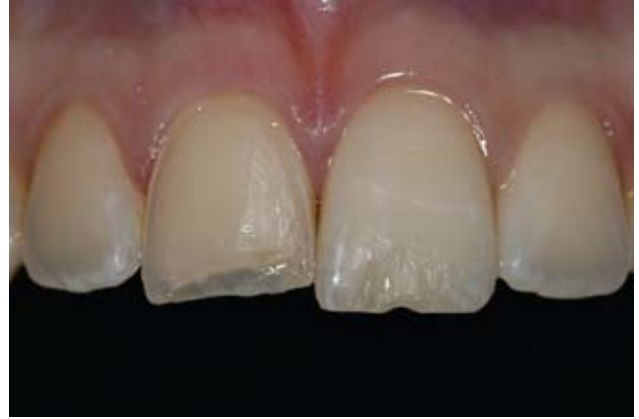

Figure 20: Removal of the existing composites revealed a large Class IV fracture extending near the gingival margin on the right central incisor.

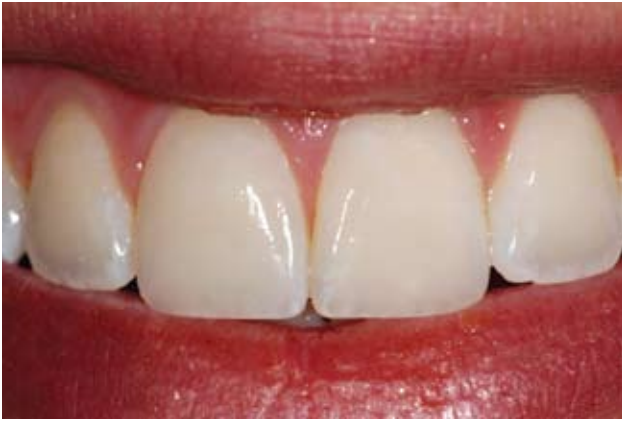

Figure 21: After whitening all her teeth, the final restorations were esthetically pleasing and exhibited characterization and polychromicity near the incisal edges.



Figure 22: The patient was very pleased with the final results and the overall enhancement of her smile.

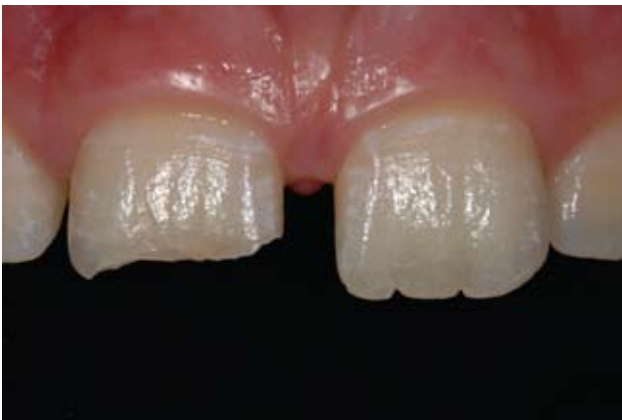

Figure 23: The right central incisor was fractured horizontally in an accident but retained vitality.

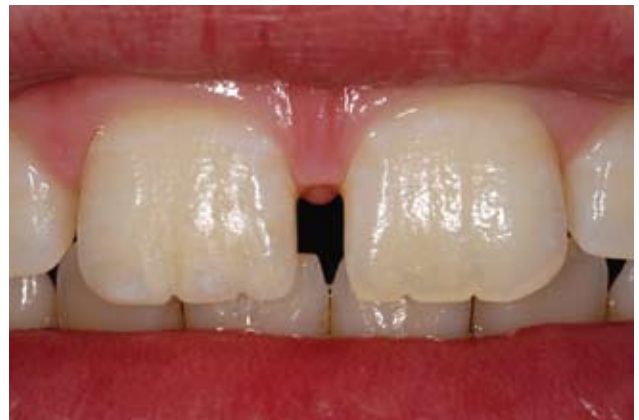

Figure 24: The conservative Class IV composite restoration did not require the removal of any additional tooth structure and was esthetically acceptable.



Figure 25: The patient was happy with her "new tooth" and pleased to smile naturally again.

layers of white tints. The final restoration was an acceptable replication of both the form and function of the natural central incisor (Figs 24 & 25).

CONCLUSION

The restoration of the anterior dentition requires knowledge of both indirect and direct restorative materials. In the case of a single, highly polychromatic anterior tooth, color matching and overall esthetic outcomes may be superior using a direct resin restorative method. The development of new anterior composites allows restorations to be more accurate and predictable, while simultaneously enabling natural tooth structure to be rejuvenated in a manner that is conservative and highly esthetic.

References

1. Morgan M. benefits beyond beauty: A perspective on posterior resin restorations. *Journal of Cosmetic Dentistry* 1(4):51-59, 2000.
2. Jackson RD. *Advanced Posterior Esthetics* [course]. Presented at the Las Vegas Institute for Advanced Dental Studies; Las Vegas, NV, November 3-6, 1999.
3. Jackson RD. A restorative alternative: Esthetic inlays and onlays. *J Esthet Dent* 8(3):114-119, 1996.
4. Leinfelder KF. Posterior composite resins: The materials and their clinical performance. *JADA* 126(5):663-664, 667-668, 1995.
5. Fahl N Jr. Optimizing the esthetics of Class IV restorations with composite resins. *J Can Dent Assoc* 63(2):108-115, 1997.
6. Dietschi D, Jacoby T, Dietschi JM, et al. Treatment of traumatic injuries in the front teeth: Restorative aspects in crown fractures. *Pract Perio Aesthet Dent* 12(8):751-758, 2000.
7. Dietschi D. Free-hand bonding in the esthetic treatment of anterior teeth: creating the illusion. *J Esthet Dent* 9(4):156-164, 1997.
8. Fahl N Jr. *Anterior Composite Artistry* [lecture]. Presented at the Center for Esthetic Excellence; Chicago, IL, February 6, 2004.
9. Jackson RD. Understanding the characteristics of naturally shaded composite resins. *Pract Proced Aesthet Dent* 15(8):577-585, 2003.
10. Blank JT. Simplified techniques for the placement of stratified polychromatic anterior and posterior direct composite restorations. *Compend Contin Educ Dent* 24(2 Suppl):19-25, 2003.
11. Dietschi D. Layering concepts in anterior composite restorations. *J Adhes Dent* 3(1):71-80, 2001.
12. Vanini L. Light and color in anterior composite restorations. *Pract Perio Aesthet Dent* 8(7):673-682, 1996.

Editor's Note: This article was based on a corporate workshop by Bisco Dental Products, presented at the AACD's Excellence in Cosmetic Dentistry 2008, in New Orleans, Louisiana. *AF*

